

Periodontally Accelerated Molar Distalization With Miniscrew Assisted Memory Screw: A Pilot Study

Bayram Çörekçi, DDS, PhD;^{1,*} Celal Irgin, DDS, PhD;² Koray Halicioğlu, DDS, PhD;²
Yasin Hezenci, DDS;³ Saffet Dursun, DDS;³ and Fatih Özcan, DDS, PhD⁴

ABSTRACT

Objective: To examine the treatment effects of a miniscrew assisted memory screw system supported by piezoincision for the noncompliance molar distalization of maxillary first molars in patients with Class II malocclusion.

Materials and Method: Nine subjects with skeletal Class I dental Class II malocclusion were treated. An anchorage unit was prepared using two miniscrew that were placed just behind a line connecting the first premolars at the mesial contact point. The memory expansion screw (500 g), and two miniscrews placed parallel to the occlusal plane provided stable, 4-point support for the appliance. Piezoincision was performed immediately after the appliance as cemented. Four midlevel incisions were made under local anesthesia between the roots of the teeth on the buccal side of the maxillary alveolar bone from the mesial first premolar to the second molar. A 3-mm piezoelectrical corticotomy was then performed by inserting the tip of Piezotome into each of these openings. Screw activation was started the following day. Skeletal and dental changes were measured on cephalograms, and dental casts were obtained before and after distalization.

Results: Upper first molars were successfully distalized in approximately 4.6 months and the mean distalization at the end was 4.98 mm. The average distal tipping of the upper first molars was 7.75°. No statistically significant changes were noted in the sagittal position of the maxilla or in the position of the upper incisors as a result of treatment. The maxillary first molars also moved palatally (1.13 mm), but no significant distal rotation occurred.

Conclusion: This system provided an efficient distalization method for posterior teeth and showed no anchorage loss. Molar tipping and palatal movement were observed as side effects in the patients. (*Turkish J Orthod* 2013;26:162–168)

KEY WORDS: Distalization, Memory Screw, Miniscrew, Piezoincision

INTRODUCTION

The treatment options for skeletal or dental Class II malocclusions include extraction or nonextraction protocols, which are used to gain space in the upper dental arch and to create a Class I canine relationship.^{1,2} Nonextraction treatments usually focus on distalization of the maxillary molars, generally through the use of esthetic-dependent extraoral headgears, removable appliances with springs, and Class II intermaxillary elastics.^{3–7} However, these modalities all need very good patient compliance to accomplish adequate treat-

ment results.^{3,6,8} Poor patient cooperation has prompted orthodontists to develop and use alternative mechanics and appliances that minimize requirements for patient compliance and improve the prediction of treatment outcome.^{4,8}

Lack of compliance is handled today with a wide variety of intramaxillary treatment options that can distalize the maxillary molars, such as Keles Slider, distal jet, pendulum appliance, repelling magnets, Wilson arch, Jones jig, compressed coil springs, first

¹Assistant Professor, Chair, Abant İzzet Baysal University, Faculty of Dentistry, Department of Orthodontics, Bolu, Turkey

²Assistant Professor, Abant İzzet Baysal University, Faculty of Dentistry, Department of Orthodontics, Bolu, Turkey

³Research Assistant, Abant İzzet Baysal University, Faculty of Dentistry, Bolu, Turkey

⁴Associate Professor, Chair, Department of Oral and Maxillofacial Surgery, Faculty of Dentistry, Abant İzzet Baysal University, Bolu, Turkey

***Corresponding author:** Bayram Çörekçi, Abant İzzet Baysal Üniversitesi, Diş Hekimliği Fakültesi, Ortodonti Anabilim Dalı, Gölköy Kampüsü, Bolu, 14100 Turkey. Tel: +90-374-254 10 00 E-mail: bayramcorekci@yahoo.com

To cite this article: Çörekçi B, Irgin C, Halicioğlu K, Hezenci Y, Dursun S, Özcan F. Periodontally accelerated molar distalization with miniscrew assisted memory screw: a pilot study. *Turkish J Orthod*. 2013;26:162–168. (DOI: <http://dx.doi.org/10.13076/TJO-D-13-00016>)

Date Submitted: November 2013. Date Accepted: December 2013.

Copyright 2014 by Turkish Orthodontic Society

class appliance, molar distalizing bows, and orthodontic or miniscrew implants.^{4-6,9-14}

Intraoral distalization methods—namely, noncompliance distalization methods—are evidence-based treatment protocols that are reliable and effective for maxillary molar distalization.^{4,6} Nonetheless, pure molar distalization with these appliances should be assessed with caution because their first and undesirable side effect is generally anchorage loss.^{4,8} The maxillary anchorage loss may cause such problems as anterior incisor proclination that increases the overjet, posterior distally rotated molar crowns, and mesially tipped premolars and canines.^{4,10-12} The different treatment modalities and techniques can cause these side effects.

Skeletal anchorage devices can be an efficient alternative for preventing anchorage loss in all of these mechanics and may decrease the side effects and treatment time, thereby improving treatment results.^{4,15} The literature indicates that skeletal anchorages with open coil springs have been used effectively to distalize maxillary molars as noncompliance appliances.^{6,8,11} Activation of these appliances generally requires an orthodontist. The memory Hyrax screw also uses nickel-titanium (Ni-Ti) coils and can produce continuous and physiological forces as large as 500 g.¹⁶ Orthodontic distalization force of the memory screw can also be accumulated by patient activation, with no need for the orthodontist. At present, no study has investigated the effectiveness of combining memory hyrax screw and mini-implant for distalizing maxillary molars.

At present, investigators are greatly interested in noncompliance treatments and relatively shortened treatment times. In a biological system, shortening the time for treatment or facilitating tooth movement depends on an unclear local biological environment and response.¹⁷⁻¹⁹ The local biological response was promoted by the introduction of several new approaches such as corticision, piezoincision, corticotomies, and osteotomies.^{17,19-21} The main emphasis of these procedures was to increase the activity of local inflammatory markers in response to orthodontic forces.²² When the expression of inflammatory markers was increased by some local intervention, this promoted osteoclast activity and accelerated the rate of tooth movement.^{22,23} Piezoincision is a minimally invasive, periodontally accelerated orthodontic tooth-movement procedure that speeds up healing, particularly after a surgical wound of the cortical bone.²⁰ Hitherto, no study has evaluated the combination of piezoincision and a

hybrid memory screw distalization unit for maxillary molar distalization in early permanent dentition. We investigated whether this phenomenon occurs in patients with Class II malocclusion by designing a pilot clinical trial to evaluate the rate of molar distalization with a mini-implant–assisted memory screw unit with piezoincision.

MATERIALS AND METHODS

A total of 9 consecutive patients (mean age = 12.96 ± 2.19 years) with Class II malocclusion were included in the study. All patients were treated by the same clinician (B.C.) at the Department of Orthodontics, School of Dentistry, Abant İzzet Baysal University of Bolu in Turkey. Inclusion criteria included no past orthodontic treatment, no absence of second molars, no crossbites, no severe carious lesions, good oral hygiene, and minimal or no crowding in the lower dental arch.

All 9 patients had a half-cusp molar relationship and received no treatment for the mandible during the examination period. An informed consent form was signed by all parents and guardians of the patients after they received detailed information about the planned clinical trial and their children's future orthodontic treatment. The trial was approved by the ethical committee of the School of Medicine of Abant İzzet Baysal University of Bolu and was conducted according to its guidelines.

The new approach was initiated with the planning of an anchorage unit, which was prepared by placing 2 miniscrews. Local anesthesia was applied palatally in the anterior palate. To insert the miniscrews, the palatal mucosa was punched just behind a line connecting the first premolars at the mesial contact point about 6–8 mm behind the incisal papillae. The miniscrews were placed less than 3 mm away from the midpalatal suture to ensure adequate bone thickness.^{24,25} Pre-drilling of about 4 mm was applied to punch holes with a drill (1 mm in diameter). Tomas mini-implants (Tomas Anchorage System, Dentauro, Ispringen, Germany) 2×8 mm (1.6 mm in diameter) in size were inserted manually at approximately parallel angulations. Orthodontic bands were then placed to the maxillary first molars. Stainless steel abutments (Trimed, Ankara, Turkey), which allow direct silver soldering of the memory expansion screw' arms, were placed in order to take a silicon impression and were also used to transfer the mini-implant location to a plaster cast. To identically reproduce a patient's mouth, the molar bands and

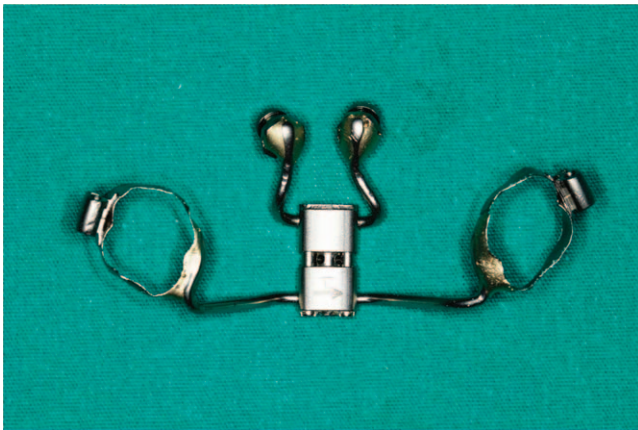

Figure 1. Fabricated hybrid memory distalization unit.

transfer miniscrews were fitted in abutments in silicon and a high-strength dental stone cast was made.

The abutments were placed over the miniscrew heads, and then a split memory screw (Spring force: 500 g, Palatal split screw type 'S'; Forestadent, Pforzheim, Germany) was bent and adapted to the abutments and the molar bands at a 90° angle to produce the distalization force. A hybrid memory distalization unit was fabricated by silver soldering between the abutments, memory screw, and molar bands (Figure 1). It was luted with light-curing glass ionomer cement (Ultra Band Lock, Reliance, IL, USA). This hybrid memory distalization unit, with its 2 miniscrews and 2 molar bands, provided stable and 4-point support for the appliance when placed parallel to occlusal plane.

Piezoincision was performed immediately after the appliance was cemented. Four midlevel vertical incisions (4 mm) were made under local anesthesia between the roots of teeth on the buccal side of the maxillary alveolar bone from the mesial aspect of the first premolar to the mesial aspect of the second molar in each quadrant using a no. 15 surgical blade (Figure 2). A piezo surgical knife (Piezotome, type BS1, Piezon Master Surgery, EMS, Nyon, Switzerland) was then inserted into these openings and a piezoelectrical corticotomy was performed to a depth of 3–4 mm.²⁰ No sutures, antibiotics, or analgesics were used after surgery. Only one patient complained of pain and local inflammation on one side the day after surgery and took some medication for 5 days. Piezoincision was performed at the Department of Oral and Maxillofacial Surgery, School of Dentistry, Abant İzzet Baysal University.

After a 1-day latency period, the frontal split screw was activated once a day by a 90° turn (0.20 mm/day) for 10 days; this was performed by each

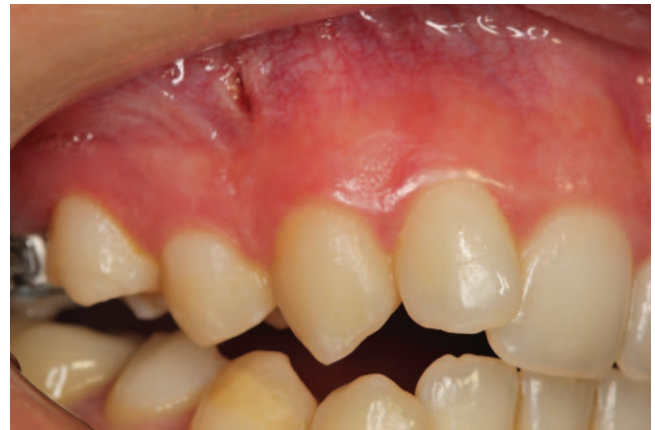

Figure 2. An example of the piezoincision openings.

patient's guardian. After that, activation was performed twice a week. In total, 32 activations were done if needed. Deactivation of the split screw was not needed because of the nature of the memory expansion screw, which does not allow activation relapse. All Class II malocclusions were corrected to super Class I by this miniscrew-supported hybrid memory distalization unit, which was left *in situ* for retention (Figure 3). Lateral cephalometric radiographs and dental casts were obtained for recording.

Pre- and posttreatment lateral digital cephalograms (Vatech Pax Uni3D, Gyeonggi d.d.o., Korea) of the 9 patients were taken with using the same equipment, conditions and operator and then evaluated by one author (C.I.) using cephalometric analysis software (Ax.Ceph, AUDAX d.o.o., Ljubljana, Slovenia) to eliminate the interobserver error factor. A horizontal reference plane was constructed with a 7° angle to the sella-nasion plane and the vertical reference plane was constructed perpendicular to the horizontal reference plane at the sella point for measurement. In

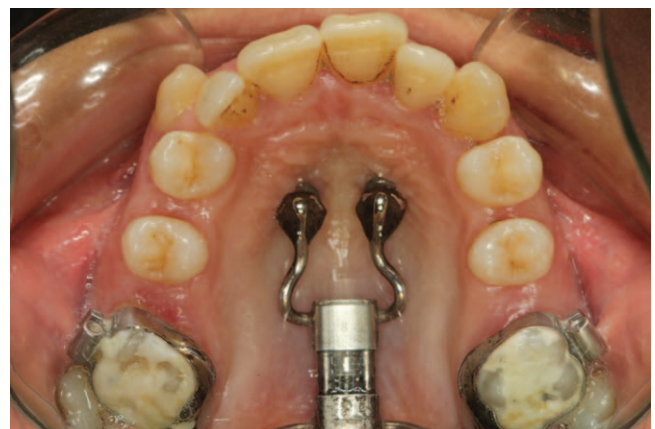

Figure 3. An example of a hybrid memory distalization unit in retention.

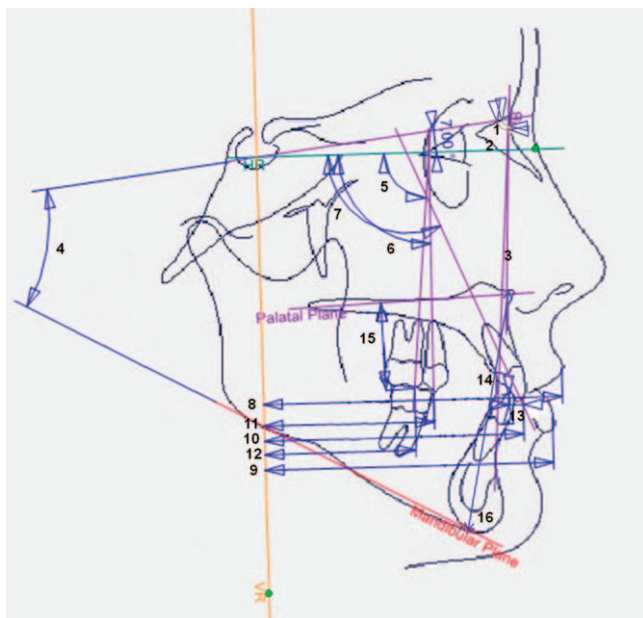


Figure 4. Cephalometric measurements used in the study.

total 16 measurements were evaluated in the cephalometric analysis (Figure 4).

Pre- and posttreatment dental casts were scanned to create 3-dimensional (3D) models using a 3D scanner (R700 Scanner, 3Shape A/S, Denmark), which were assessed using 3D analyzer software (OrthoAnalyzer 2013, 3Shape A/S) by same operator (C.I.). Molar movement in the transverse plane (6-Midline (ML)) and molar rotation (6-ML rotation) were evaluated (Figure 5).

Each measurement was traced twice, blinded, with a 2-week interval between the first and second readings, as recommended by Baumrind and Frantz.²⁶ The data were averaged separately for each period (T1 and T2) for descriptive analysis. The Shapiro-Wilk test was used to confirm the normal distribution of the data. Pre- and posttreatment differences were tested for statistical significance using the Wilcoxon signed rank test. The level of significance used was 5%. All analyses were performed using SPSS version 17 (SPSS Inc, Chicago, IL, USA).

RESULTS

A super Class I relationship was obtained for the maxillary first molars in all patients. The mean distalization period to achieve a super Class I molar relationship was 4.6 months.

Pretreatment and posttreatment means and standard deviations of the variables under investigation

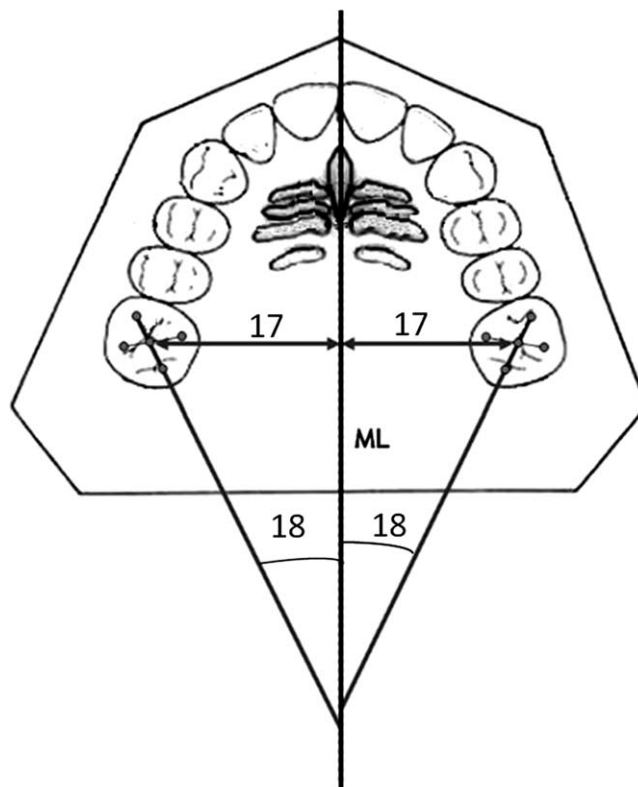


Figure 5. Measurements on the dental casts.

group, their differences, and their statistical significances are listed in Table 1.

Based on the changes between T1 and T2, the piezoincision-assisted hybrid memory distalization unit created a distalization of the maxillary first molars of about 4.98 mm ($p < 0.05$). The rate of distal tipping for the maxillary first molar was measured at 7.75° ($p < 0.05$). The average molar movement rate was 1.09 mm per month. Statistically significant vertical intrusion of the maxillary first molar (U6-PP) was observed (1.43 mm, $p < 0.05$).

The anchorage loss of the anterior dentition by means of the sagittal movement of the maxillary incisors or the increase in overjet was not statistically significant. A slightly nonsignificant proclination of the incisors was observed.

The vertical relationship of the maxilla and the mandible (ANS-Me) was significantly changed after treatment but the sagittal position of the maxilla and mandible was not changed after distalization.

Dental-cast evaluations indicated that the movement of the maxillary first molars in the transverse plane was toward the palatal direction (1.13 mm, $p < 0.05$), whereas no significant distal rotations occurred.

Table 1. Comparison of cephalometric and dental cast changes before (T1) and after treatment (T2) (n = 9)

		T1		T2		Difference of Mean	Significance ^a
		Mean	SD	Mean	SD	T2-T1	P
Cephalometric variables							
1	SNA, °	79.63	3.71	80.14	3.11	0.52	NS
2	SNB, °	77.23	3.07	77.06	2.42	-0.18	NS
3	ANB, °	2.39	2.36	3.09	2.32	0.69	*
4	SN-GoMe, °	33.41	5.31	34.29	4.47	0.88	NS
5	U6-HR, °	82.22	5.19	74.47	5.85	-7.75	*
6	U5-HR, °	86.90	4.47	83.75	4.72	-3.15	*
7	U1-HR, °	107.30	7.84	108.44	8.85	1.14	NS
8	UL-VR, mm	83.41	4.89	83.98	5.01	0.57	NS
9	LL-VR, mm	79.24	4.45	79.68	4.57	0.44	NS
10	U1-VR, mm	68.23	5.89	68.94	5.95	0.71	NS
11	U5-VR, mm	48.57	4.65	45.09	4.77	3.48	*
12	U6-VR, mm	41.81	5.02	36.83	4.95	4.98	*
13	Overjet, mm	3.68	2.73	4.06	3.02	0.33	NS
14	Overbite, mm	3.47	1.64	2.59	2.22	-0.88	*
15	U6-PP, mm	17.34	3.12	15.91	2.97	-1.43	*
16	ANS-Me, mm	62.31	4.14	63.77	4.32	1.47	*
Dental cast variables							
17	6-ML, mm	22.94	1.91	21.81	2.02	-1.13	*
18	6-ML rotation, mm	34.01	4.23	34.59	4.66	0.58	NS

^a NS indicates not significant.

DISCUSSION

This pilot study was planned as a way to determine the treatment effects of piezoincision-assisted hybrid memory distalization unit on dentoalveolar and skeletal structures with Class II malocclusion in early permanent dentition. The aim of the study was to begin to fill the gap in published studies concerning the combination of piezoincision and miniscrew assisted memory screw unit for distalization of maxillary molars as a noncompliance therapy.

For this trial, some criteria were used to improve the quality of the study : (1) the inclusion criteria applied to our subjects, (2) all patients were treated by a single clinician, (3) the same operator took all lateral cephalometric radiographs using the same equipment and conditions, (4) the cephalometric radiographs and dental casts were evaluated by one experienced examiner, and (5) intraexaminer error of the method was reduced by performing all measurements twice in 2 weeks and averaging the data.²⁶

The main purpose of this study was to determine the efficiency of symmetric and equal distalizing forces produced by a memory hyrax screw (500 g) from the approximate center of resistance of the maxillary molars with the assistance of piezoincision. The use of this new approach produced significant maxillary first molar distalization after

4.6 months, as the cephalometric radiographs showed clearly different measurements (4.98 mm) in relation to the patients' pretreatment condition. The rate of molar movement was 1.09 mm per month, which is actually equal to or even higher than findings reported by some authors for noncompliance appliances with skeletal anchorage.⁴

A recent meta-analysis study stated that the range of average molar distal movement was from 3.9 to 6.4 mm and treatment time ranged from 5.0 to 7.8 months for varied maxillary molar distalization appliances with skeletal anchorage.⁴ The average amount of distal movement was 0.81 mm/mo (range = 0.11–1.28 mm/mo). The mean distal movement range in the present study was relatively high (1.09 mm/mo) compared with the rates documented in other studies in the literature. This may be a result of the piezoincision, which, like other cortical interventions, such as micro-osteoperforation, may increase the level of inflammatory markers.²³ These markers can act in some ways as macrophages or osteoclasts in the surrounding tissue of tooth.²⁷ Other markers have been related to local healing and activation of osteoclasts during orthodontic tooth movement.²⁸ These markers all help to amplify or maintain the inflammatory response and stimulation of the bone resorption machinery.²³ The current approach with piezoincision may serve to increase

the expression of these inflammatory factors, as reported by Alikhani et al.,²³ suggesting that the use of a local surgical intervention may increase release of these factors, giving rise to higher osteoclast activation and a subsequently higher rate of tooth movement.^{23,29}

It has been stated that to produce pure bodily distal molar movement or minimum distal tipping, the force vector must be positioned 10–13 mm apical to the occlusal surface of the maxillary molar and pass through or close to its center of resistance.³⁰ In a meta-analysis study, the mean molar distal tipping ranged from 3.0° to 12.2° for a variety of maxillary molar distalization appliances with skeletal anchorage.⁴ However, in the current study, bodily molar distalization was not noted and there was a significant distal crown tipping of 7.75° in relation to horizontal reference plane. The distal tipping of the molar crowns in the treatment group might be reflect the following: (1) the memory screw can produce physiological force (500 g) and continuous force, so that biologic response of the alveolar to the distalization force may be delayed as expected; (2) the rigid arms of the screw did not allow a spontaneous upright position of the molars during the distalization period. The distal tipping of the molar crowns may be disadvantageous for anchorage but, as shown in the present study, the distalization appliance can be used as a retention appliance and thus any possible anchorage loss can be prevented by leaving the appliance *in situ*.

When assessing the vertical dentoalveolar cephalometric changes, a slightly significant intrusion of the active (maxillary molars) unit (–1.43 mm) and a slightly significant reduction of overbite (–0.88 mm) in patients were evident. These changes paralleled those observed in other studies that used various noncompliance distalization appliances.⁴ One possible way to understand intrusion of the maxillary molars may be by considering the nature of the new appliance design; there is a small space (2–3 mm) between the memory screw and the plate that could be decreased by tongue force when swallowing during the distalization period. Thus, an unexpected intrusion force could be produced. Although distal tipping of the molars with intrusion was a side effect of the new mechanic and could cause bite opening, this was minimal and clinically not important. The situation might be an advantage where the bite of the patient is critical, but in general, the appliance must be placed in close relationship with the palate to prevent these side effects.

Studies with the miniscrew-supported anchorage system showed spontaneous distal movement for premolars (–3.1 to –5.4 mm) and no anchorage loss.⁴ The well-known reason is the transeptal fibers that help to control the distal movement of the maxillary second premolars and maxillary first premolars during distalization of the maxillary first molars. The distalizations of second premolars in this study (3.48 mm) corroborate the findings of Grec et al.⁴ The distalization of the second premolars took place with distal tipping (3.15°), which may depend on the absence of any mechanism on the premolars and on the bite force.

In addition, no significant sagittal anchorage loss or increase in anterior crowding occurred after distalization with the new appliance. These findings were always observed in similar studies that applied stationary anchorage using either orthodontic implants or miniscrew implants.^{4,30}

The dental cast analysis revealed no significant molar crown rotation after distalization with the hybrid memory screw unit; however, assessment of maxillary first molar movement in the transverse dimension indicated a decrease in the intermolar width as both left and right molars moved palatally (–1.13 mm). The lack of molar rotation and the narrowing of the intermolar width after distalization can be ascribed to the rigid arms of the memory screw (soldered to the molar bands), which guided the molars to hold together as a pretreatment condition of the posterior part of the maxillary dental arch. This result may be a major drawback of the appliance, but this problem can be resolved by bending the posterior arms of the memory screw (bands part) 1–2 mm buccally as a headgear facebow before cementing.

To improve and support clinical performance, the distalization units were left *in situ*, and this provided retention for the distalized molars. The second phase of treatment with fixed appliances may begin as soon as possible after or during distalization because the patients undergoing treatment were in early permanent dentition; this is a great advantage of this approach. The piezoincision intervention also gives a further advantage for rapid alignment and distalization of other teeth if it is possible to begin their distalization.

CONCLUSIONS

In conclusion, the present findings indicate that a mini-implant assisted memory screw unit with

piezoincision is an efficient appliance for distalization of the maxillary first molars in patients with Class II malocclusion in the early permanent dentition and requires no patient compliance. The distalization takes place without distal rotation, extrusion of the molars, or anchorage loss. Distal tipping of the molar crowns and narrowing of the intermolar width can occur; however, these side effects could be easily rectified in the second phase of treatment with fixed appliances.

REFERENCES

- Hayasaki SM, Castanha Henriques JF, Janson G, de Freitas MR. Influence of extraction and nonextraction orthodontic treatment in Japanese-Brazilians with class I and class II division 1 malocclusions. *Am J Orthod Dentofacial Orthop*. 2005;127:30–36.
- Janson G, Maria FR, Barros SE, Freitas MR, Henriques JF. Orthodontic treatment time in 2- and 4-premolar-extraction protocols. *Am J Orthod Dentofacial Orthop*. 2006;129:666–671.
- Egolf RJ, BeGole EA, Upshaw HS. Factors associated with orthodontic patient compliance with intraoral elastic and headgear wear. *Am J Orthod Dentofacial Orthop*. 1990;97:336–348.
- Grec RH, Janson G, Branco NC, Moura-Grec PG, Patel MP, Castanha Henriques JF. Intraoral distalizer effects with conventional and skeletal anchorage: a meta-analysis. *Am J Orthod Dentofacial Orthop*. 2013;143:602–615.
- Keim RG, Berkman C. Intra-arch maxillary molar distalization appliances for Class II correction. *J Clin Orthod*. 2004;38:505–511.
- Keles A, Sayinsu K. A new approach in maxillary molar distalization: intraoral bodily molar distalizer. *Am J Orthod Dentofacial Orthop*. 2000;117:39–48.
- King GJ, Keeling SD, Hocevar RA, Wheeler TT. The timing of treatment for Class II malocclusions in children: a literature review. *Angle Orthod*. 1990;60:87–97.
- Papadopoulos MA, Melkos AB, Athanasiou AE. Noncompliance maxillary molar distalization with the first class appliance: a randomized controlled trial. *Am J Orthod Dentofacial Orthop*. 2010;137:e581–e586.
- Gianelly AA, Vaitas AS, Thomas WM. The use of magnets to move molars distally. *Am J Orthod Dentofacial Orthop*. 1989;96:161–167.
- Carano A, Testa M, Siciliani G. The Distal Jet for uprighting lower molars. *J Clin Orthod*. 1996;30:707–710.
- Gianelly AA, Bednar J, Dietz VS. Japanese NiTi coils used to move molars distally. *Am J Orthod Dentofacial Orthop*. 1991;99:564–566.
- Hilgers JJ. The pendulum appliance for Class II non-compliance therapy. *J Clin Orthod*. 1992;26:706–714.
- Wilson RC. Comment on rapid molar distalization. *Am J Orthod Dentofacial Orthop*. 1995;107:20A–22A.
- Fortini A, Lupoli M, Parri M. The First Class Appliance for rapid molar distalization. *J Clin Orthod*. 1999;33:322–328.
- Gray JB, Steen ME, King GJ, Clark AE. Studies on the efficacy of implants as orthodontic anchorage. *Am J Orthod*. 1983;83:311–317.
- Wichelhaus A, Geserick M, Ball J. A new nickel titanium rapid maxillary expansion screw. *J Clin Orthod*. 2004;38:677–680; quiz 671–672.
- Krishnan V, Davidovitch Z. Cellular, molecular, and tissue-level reactions to orthodontic force. *Am J Orthod Dentofacial Orthop*. 2006;129:461.e1–32.
- Frost HM. The regional acceleratory phenomenon: a review. *Henry Ford Hosp Med J*. 1983;31:3–9.
- Kim SJ, Park YG, Kang SG. Effects of corticision on paradental remodeling in orthodontic tooth movement. *Angle Orthod*. 2009;79:284–291.
- Dibart S, Sebaoun JD, Surmenian J. Piezocision: a minimally invasive, periodontally accelerated orthodontic tooth movement procedure. *Compend Contin Educ Dent*. 2009;30:342–344, 346, 348–350.
- Kisnisci RS, Iseri H, Tuz HH, Altug AT. Dentoalveolar distraction osteogenesis for rapid orthodontic canine retraction. *J Oral Maxillofac Surg*. 2002;60:389–394.
- Teixeira CC, Khoo E, Tran J, Chartres I, Liu Y, et al. Cytokine expression and accelerated tooth movement. *J Dent Res*. 2010;89:1135–1141.
- Alikhani M, Raptis M, Zoldan B, Sangsuwon C, Lee YB, et al. Effect of micro-osteoperforations on the rate of tooth movement. *Am J Orthod Dentofacial Orthop*. 2013;144:639–648.
- Wilmes B, Nienkemper M, Drescher D. Application and effectiveness of a mini-implant- and tooth-borne rapid palatal expansion device: the hybrid hyrax. *World J Orthod*. 2010;11:323–330.
- Ludwig B, Glasl B, Bowman SJ, Wilmes B, Kinzinger GS, Lisson JA. Anatomical guidelines for miniscrew insertion: palatal sites. *J Clin Orthod*. 2011;45:433–441; quiz 467.
- Baumrind S, Frantz RC. The reliability of head film measurements. 2. Conventional angular and linear measures. *Am J Orthod*. 1971;60:505–517.
- Taddei SR, Andrade I Jr, Queiroz-Junior CM, Garlet TP, Garlet GP, et al. Role of CCR2 in orthodontic tooth movement. *Am J Orthod Dentofacial Orthop*. 2012;141:153–160.
- Garlet TP, Coelho U, Repeke CE, Silva JS, Cunha Fde Q, Garlet GP. Differential expression of osteoblast and osteoclast chemoattractants in compression and tension sides during orthodontic movement. *Cytokine*. 2008;42:330–335.
- Fuller K, Kirstein B, Chambers TJ. Murine osteoclast formation and function: differential regulation by humoral agents. *Endocrinology*. 2006;147:1979–1985.
- Papadopoulos MA. Orthodontic treatment of Class II malocclusion with miniscrew implants. *Am J Orthod Dentofacial Orthop*. 2008;134:604 e601–e616; discussion 604–605.